



## **Yorkshire & Humber Neonatal ODN (South) Clinical Guideline**

**Title:** Extravasation Injuries in Neonates

**Author:** Dr Pauline Adiotomre, Lynn Elliot

**Date Written:** March 2005,

Reviewed July 2018 by Dr Pauline Adiotomre & Dr Cath Smith

Reviewed July 2021 by Dr A. Sulieman, Dr K Thompson & Dr Cath Smith

**Next Review Date:**

**Date Ratified:** 6 September 2018

**This clinical guideline has been developed to ensure appropriate evidence based standards of care throughout the Yorkshire & Humber Neonatal ODN (South). The appropriate use and interpretation of this guideline in providing clinical care remains the responsibility of the individual clinician. If there is any doubt discuss with a senior colleague.**

**Best practice recommendations represent widely used evidence-based practice and high quality standards that all Neonatal Units across the Network should implement. Subsequent suggested recommendations may be put into practice in local units. However, alternative appropriate local guidelines may also exist.**

### **A. Summary**

Aim of guideline

Prevention and management of extravasation injuries.

Extravasation injuries require review regarding the need for treatment.

Treatments include

Dressings-

hydrocolloids

hydrogels

Topical therapies-

2% Glyceryltrinitrate ointment (GTN).

Glyceryltrinitrate patch

Hyaluronidase irrigation

The treatment required will depend on the drug extravasated, the site and extent of the injury and the gestation of the infant. Note hyaluronidase is no longer recommended for use in extremely preterm infants.

## **B. Full guideline**

### **1. Background**

#### **EPIDEMIOLOGY OF EXTRAVASATION INJURIES**

Extravasation is the non-intentional leakage of infused fluid into surrounding tissue which may cause tissue damage<sup>1</sup>.

The prevalence of extravasation injuries causing skin necrosis in 31 regional neonatal units in the United Kingdom was 38 per 1000 babies<sup>2</sup>.

Infants of 26 weeks gestation or less were more likely to have injuries, which was likely to occur when parenteral nutrition was given via intravenous cannulae. Other fluids implicated in extravasation injuries were 10% dextrose with calcium and blood. Dopamine and other vasoactive fluids can also cause this injury with tissue ischaemia<sup>3</sup>. Preterm babies are at high risk as they have most immature skin which is easily damaged, require longer duration of intravenous therapy and have difficult venous access.

### **2. Aim**

Prevention and management of extravasation injuries.

### **3. Areas outside remit if applicable**

None applicable

### **4. Core guideline:**

#### **4.1 PREVENTION**

- Use percutaneous long lines for the administration of total parenteral nutrition and glucose concentrations greater than 12.5%. When running dextrose 12.5% peripherally the site should be very closely observed and observations documented. Consideration should be given to placing central access to avoid extravasation.
- Avoid scalp vein cannula where possible
- Secure cannulae with transparent dressing to ensure visibility at insertion site.
- Hourly recording of observation of cannula site for oedema, firmness or discolouration.
- Percutaneous long line for long term calcium supplementation. However, if calcium supplementation is only short term, this can be given via a peripheral cannula, the site of which must be monitored closely

There is currently no evidence that monitoring infusion pump pressures reduces the incidence of extravasation injuries<sup>4</sup>.

## **4.2 STAGING OF EXTRAVASATION<sup>5</sup>**

### **Stage      Characteristics**

1	Absence of redness and swelling. Flushes with difficulty. Take IV device out.
2	Slight swelling at site. Presence of redness. Good pulse below site. 1-2 seconds capillary refill below site. Take IV device out. Elevate extremity.
3	Moderate swelling above or below site. Blanching. Good pulse below extravasation site. 1-2 seconds capillary refill below extravasation site. Skin cool to touch. Follow management below.
4	Severe swelling above or below site. Blanching. Pain at site. Decreased or absent pulse. Capillary refill greater than 4 seconds. Skin cool to touch. Skin breakdown or necrosis. Follow management below.

## **4.3 WOUND ASSESSMENT<sup>1</sup>**

This should include the site, size of injury, level of exudate, state of healing and possibility of infection. Exudate is more pronounced during the inflammatory phase of wound healing and should be graded as low, medium or large. This is however subjective.

There are 4 stages of wound healing (wound status)-:

- a) Necrotic stage - the surface of wound may initially be covered with devitalised tissue which is unbroken if area of damage is away from the cannulation site.
- b) Slough stage - slough is composed of dead white cells and can be mistaken for pus often with lack of signs of infection such as redness, swelling, heat and loss of movement.
- c) Granulating stage - granulation tissue develops quickly when wound bed is clean and gives a red appearance. This is highly vascular and bleeds easily if damaged. Care should be taken during dressing change or handling to prevent damage and bleeding.
- d) Epithelisation stage - this is the last stage of healing when the epithelial cells move from the wound edges towards the centre. Wound bed has a pink appearance at this stage.

#### **4.4 MANAGEMENT**

Stop the intravenous infusion. Take the IV device out after an attempt has been made to aspirate the area through the device.

There is no consensus on the management of extravasation injuries in babies. From the survey in 31 regional neonatal units common treatments were-

- Exposing wounds to the air
- Infiltration with hyaluronidase and saline
- Occlusive dressing <sup>2</sup>.

Leaving the wound exposed to the air is not considered an optimal treatment as dry scab is thought to delay epithelisation. Infiltration with hyaluronidase and saline<sup>6</sup> is an invasive procedure and British National Formulary has advised caution in the use of hyaluronidase in infants<sup>7</sup> and to control speed and total volume and therefore avoid overhydration especially in renal impairment.

Although occlusive dressings keep the wound moist which aids healing, no clinical trials have compared the outcome of treatment with occlusive dressings to that of infiltration with hyaluronidase and saline.

Features of optimum dressing<sup>1</sup>

- Small dressing size or dressing that can be cut to size.
- Can be used in a humidified environment.
- Allows full range of movement at joint sites.
- Minimum risk of further tissue damage on removal.
- Reduces epithermal water loss through wound bed

#### **4.5 WOUND DRESSING**

Those currently used are:

- Hydrocolloids

These have been shown to be beneficial in the treatment of extravasation injuries in the preterm population<sup>8</sup>. They have many of the features of an optimum dressing with an extended wear time of 7 days which is achievable during the granulation and epithelisation stages for wound healing. Because the absorption properties are limited dressing will need to be changed daily when level of exudate is high to prevent strike through. Hydrocolloid dressings are suitable for softening eschars or promoting granulation. Examples of hydrocolloids are:- Duoderm and Granuflex dressings with or without Granuflex paste.

- Hydrogels

These create a moist environment and lead to reduced scarring when used in preterm infants<sup>9</sup>. Hydrogels prevent the growth of bacteria and have a mild bactericidal property. The gel is applied directly to the extravasation injury and either covered with a film dressing (like tegaderm or opsite) or the affected limb is placed inside a sterile transparent plastic bag. Additional gel may be delivered into the bag with a syringe and a quill to ensure the wound is covered at all times<sup>10</sup>. Neck of bag should be closed using surgical tape but ensure the tape doesn't come in contact with the baby's skin. Dressing should be changed every 2 to 3 days but daily if any clinical evidence of wound infection. In this case appropriate antibiotics should be initiated.

To change the dressing slide the bag off the limb and irrigate wound with sterile isotonic saline. It is not necessary to dry the wound. One of the hydrogels is intrasite gel.

- Film dressings

Film dressings like tegaderm and opsite should be used as secondary dressings over hydrogels.

- Dry dressing is considered not to be effective.

#### **4.6 OTHER STRATEGIES THAT CAN BE CONSIDERED OR USED**

##### **First line:**

- Glyceryl Trinitrate patch<sup>13,14</sup>

GTN patch can be used to manage extravasation injury associated with intense local vasoconstriction. Glyceryl trinitrate (GTN) is a powerful local vasodilator and half a 5mg patch can be applied to the affected area. Assess the site every hour for the first two hours, then 12 hourly. Patch must be changed every 24 hours. (Cut the patch in half and discard the remainder).

##### **Second line (and for areas unsuitable for treatment with patch):**

- 0.4% Glyceryl trinitrate ointment.

Apply a thin layer of the 0.4% ointment to the affected area two to three times each day.

Apply a thin film to the ischaemic area(s) using gloves. If the baby is on phototherapy, cover area(s) with a small piece of gauze to prevent an increase in absorption.

This is used for severe peripheral tissue ischaemia caused by vasospasm from indwelling arterial catheterisation or dopamine (or other vasoactive drugs) extravasation. Glyceryl trinitrate is well absorbed topically through intact skin. It causes relaxation of the vascular smooth muscle and increases collateral circulation to localized areas of peripheral ischaemia<sup>3</sup>. Local vasodilating effects are often noted 15 to 30 minutes after topical application.

**Please see formulary for further information**

- Infiltration with hyaluronidase and saline flushout<sup>6,15,16</sup>

It is not advisable to use hyaluronidase in extreme preterm babies as it is felt not to provide any extra benefit<sup>1</sup> but can cause further tissue damage<sup>2</sup>. Outcome is better where irrigation with saline is done within 1 to 6 hours of the injury<sup>17,18</sup>

#### Equipment:

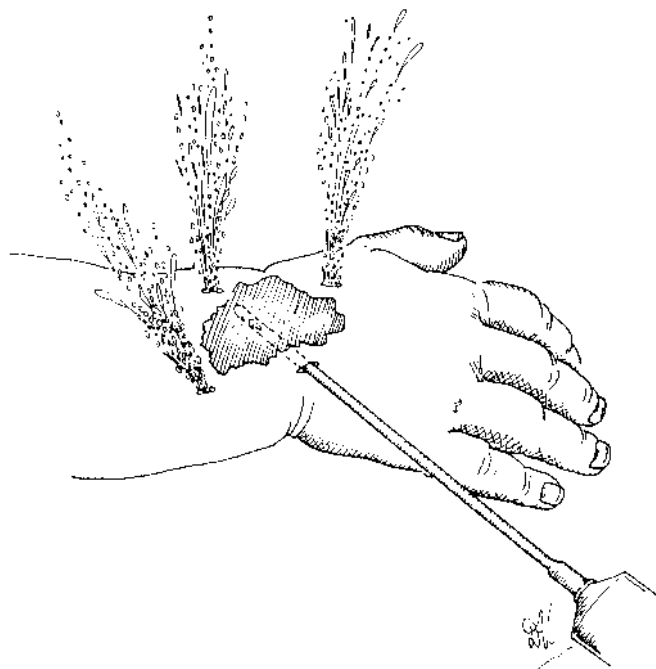
- 1% Lignocaine (up to 0.3 ml/kg maximum)
  - 1500 units/ml vial of hyaluronidase
  - Normal saline for injection
  - 1 ml syringes
  - Sterile scalpel blade
  - Size 19G cannula
  - 3 way tap
  - 20 ml syringe
  - 25G needles
  - Sterile towel
  - Dressing pack
  - Sterile gloves
  - Chlorhexidine solution
  - Water proof sheet
- Clean the discoloured area and surrounding skin with Chlorhexidine solution and place on sterile towel. Place a sterile bowl underneath towel.
  - Infiltrate area with 1% Lignocaine.
  - Inject 500-1000 units hyaluronidase into the subcutaneous tissue beneath the damaged skin. Do not use for extravasation injuries due to vaso-constrictive agents or in extreme preterm babies
  - Make four small punctures in the tissue plane with a scalpel blade around the affected area approximately 5mm long.
  - Insert the 19G cannula subcutaneously through one of the puncture sites and remove the needle
  - Using a 20 ml syringe attached to a three-way tap, inject normal saline into the area. This should flow out freely from the other three incisions.
  - Repeat the process injecting normal saline through each incision and using up to 500 ml of normal saline depending on size of wound and of baby. The following has been suggested for different weights of babies<sup>17</sup>:

<1000g	200ml
1000-2000g	300ml
> 2000g	500ml

If the limb gets oedematous, excess fluid can be removed by massaging towards the incisions.

---

- Dress area with sterile non-stick dressing such as Mepitel or Intrasite conformable gel dressing. The stab wounds should not be closed as they may drain for a while. Check wound 6 hourly for the next 1 day <sup>19</sup>
- If baby not already on antibiotics give 1 dose of IV flucloxacillin
- Elevate limb for 24 hours



saline flush out technique

A combination of strategies may be required in managing extravasation injuries. The wound dressing used will depend on the wound status. If there is clinical suggestion of infection baby should be screened for infection and started on appropriate antibiotics. Where intra-arterial line vasospasm is responsible for the peripheral ischaemia, take the line out.

#### **4.7 DOCUMENTATION**

- Detailed account of action taken when there was concern about patency of cannula or any swelling around the cannula site before the extravasation.
- Clear documentation of the causative agent, the site and size of the injury, an assessment of the wound and rationale for choice of dressing product used.
- Care plan for the treatment.
- Photograph of wound with scale included.
- Parents informed and documented.
- Complete an incident form.
- Observe and document a change in colour and decrease in swelling hourly for six hours then every six hours then at start of each shift as appropriate
- With each dressing change document state of the wound bed, change in size of wound, details of replacement dressing and planned date of review.

#### **4.8 FURTHER ACTIONS**

- Parents to be involved with wound care which should form part of the discharge planning if wound not completely healed by the time infant is ready for discharge.
- Plastic surgeons to be involved especially in extravasation injuries in term babies.
- Liaise with Tissue Viability nurse where possible.

#### **5. Audit criteria**

Adherence to guideline in managing extravasation injuries

#### **6. References**

1. Irving V. Managing extravasation injuries in preterm neonates. *Nurs Times*.2001;97(35):40 - 46.
2. Wilkins CE, Emmerson AJ. Extravasation injuries on regional neonatal units. *Arch Dis Child Fetal Neonatal Ed*.2004;89(3):F274 – 5.
3. Wong AF, McCulloch LM et al.Treatment of peripheral tissue ischaemia with topical nitroglycerin ointment in neonates. *J Pediatr*. 1992;121(6):980 – 3.
4. Gnanalingham MG, Irving V, Shaw NJ.Consensus on neonatal infusion pumps and pressure monitoring. *Arch Dis Child Fetal Neonatal Ed*. 2005;90(1):F93.
5. Montgomery LA, Haurahan K, Kottam K et al. Guideline for IV infiltrations in pediatric patients. *Pediatr Nurs* 1999 ; 25(2) : 167-9, 173-80
6. Davies J, Gault D, Buchdahl R. Preventing the scars of neonatal intensive care. *Arch Dis Child Fetal Neonatal Ed*. 1994;70:F50 – 1.
7. British National Formulary.London: BMJ Books, 2002;44.
8. Young T, et al. The use of a hydrocolloid dressing in the treatment of iatrogenic neonatal skin trauma. In: *Proceedings of the 6<sup>th</sup> European Conference on Advances in Wound Management*.1996. London: Macmillan.
9. Thomas,S et al. A new approach to the management of extravasation injury in neonates. *Pharmaceutical Journal*. 1987;239:584 – 5.
10. Thomas S, Rowe HN, et al. The management of extravasation injury in neonates.  
[www.worldwidewounds.com/1997/october/Neonates/NeonatePaper.html](http://www.worldwidewounds.com/1997/october/Neonates/NeonatePaper.html).
11. Mosalli, R et al. Topical nitroglycerine for neonatal arterial associated peripheral ischaemia following cannulation: A case report and comprehensive literature review. *Case Reports in Pediatrics*.  
[Http://dx.doi.org/10.1155/2013/608516](http://dx.doi.org/10.1155/2013/608516).



12. Plum M et al. Alternative pharmacological management of vasopressor extravasation in the absence of phentolamine. *Pharmacy and Therapeutics*. 2017;42(9) 581 – 585.
13. O'Reilly C, McKay FMA, Duffty P, Lloyd D. Glyceryl trinitrate in skin necrosis caused by extravasation of parenteral nutrition. *Lancet*. 1988 ; 2 (8610) : 565-6
14. Reynolds B.C. Neonatal extravasation injury: Case report. *Infant*. 2007; 3(6): 230-32
15. Gault D.T. Extravasation injuries. *Br J Plast Surg*. 1993; 46(2): 91-96
16. Casanova D, Bardot J, Magalon G. Emergency treatment of accidental infusion leakage in the newborn: report of 14 cases. *Br J Plastic Surgeon*. 2001; 54 : 396-9.
17. Harris P.A, Bradley S, Moss A.L. Limiting the damage of iatrogenic extravasation injury in neonates. *Plastic Reconstructive Surgery* 2001; 107(3): 893-94
18. Rose V, Turner M, Harris P.A, Moss A.L.H. Emergency treatment of accidental infusion leakage in the newborn. *Br J Plast Surg* 2002; 55(1): 89
19. NW Newborn Clinical Guideline. Recognition and management of infiltration injuries (including clysis). May 2010