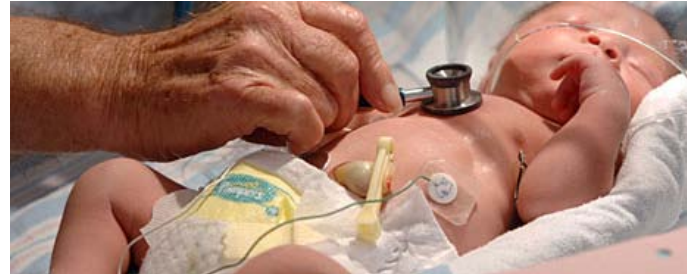

Learning Together

FEEDBACK FROM NEONATAL CLINICAL INCIDENTS

There are always lessons to be learned from clinical incidents, no matter how appropriate the management has been. The purpose of this bulletin is to highlight learning points from previous incidents to those providing care to babies day to day.



SUMMARY

There have been two recent cases in Scotland whereby peripherally inserted central catheters (PICCs) have been malpositioned resulting in extravasation of parenteral nutrition and lipid into the cerebrospinal fluid resulting in significant neurological sequelae for the infants involved.

In both cases the PICC lines were inserted in the left long saphenous vein and positioning on the initial AP x-rays was thought to be acceptable.

Both infants developed neurological symptoms (abnormal movements, irritability, seizures) as extravasation occurred.

A lumbar puncture in both cases revealed a high level of triglycerides in the cerebrospinal fluid (milky fluid obtained at LP).

Both infants have been left with profound neurological impairment and a need for intermittent catheterisation.

Lessons Learned

- These cases highlight a very rare complication of lower limb PICC line insertion
- A PICC line inserted in the left long saphenous vein can enter the left ascending lumbar vein (which runs posterior and parallel to the IVC, image 1) and can then enter the epidural plexus which are small thin walled veins. If vein perforation occurs, fluid from the PICC can enter the CSF and cause neurological damage

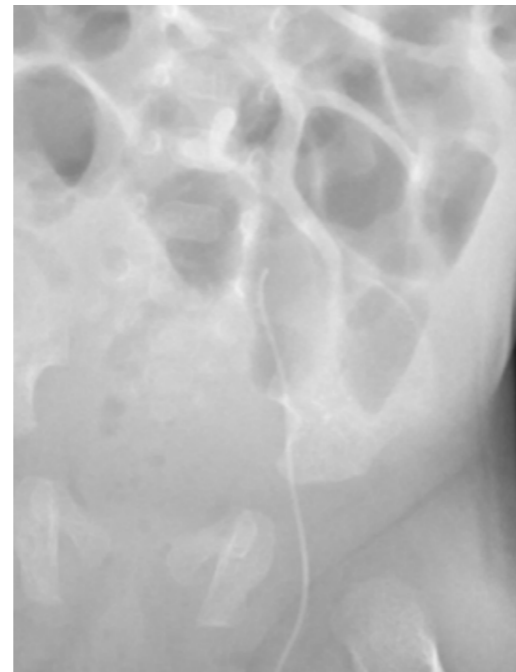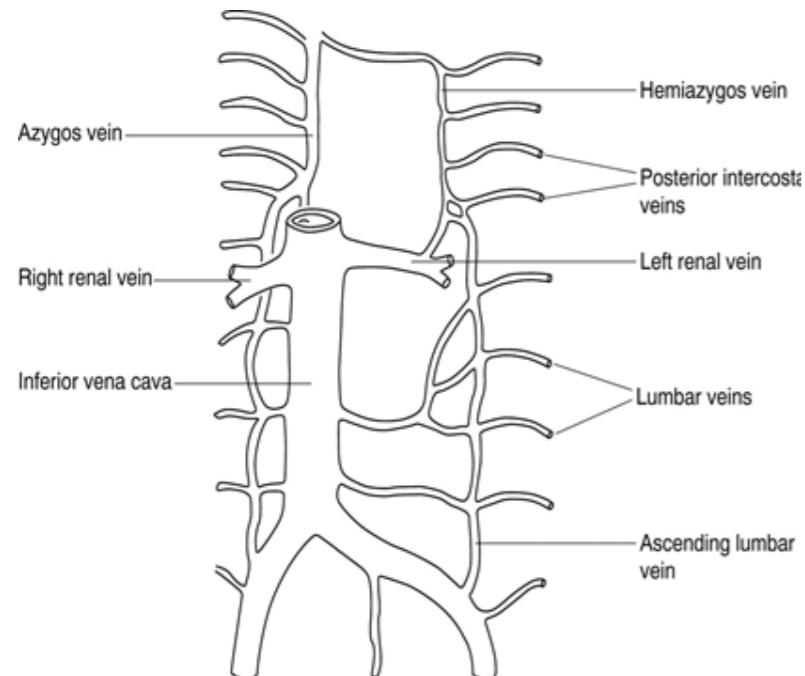


Image 1
Anatomy of left ascending lumbar vein

Image 2
A malpositioned PICC line which has not crossed the midline and remains on the left side of the vertebral column

Lessons Learned

- On AP x-ray to check line position a left saphenous PICC should track from the leg into the abdomen via the left iliac vein. It should cross the midline at L_{4/5} to run on the RIGHT side of the vertebral column in the IVC
- There should be no tortuosity in the path of the PICC line (tortuosity could be a sign it is in a small vessel)
- If a left lower limb PICC does not cross the midline as expected (image 2) or has a tortuous course (image 3), consider a lateral X-ray and discussion with radiology
- In the case of PICC malposition a lateral x-ray will demonstrate posterior deviation of the line towards the vertebral column (image 4)

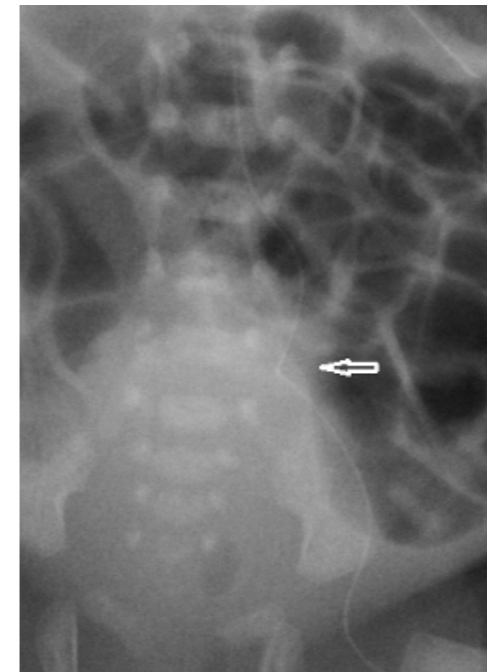


Image 3
A PICC line showing a tortuous course (arrow) and not crossing the midline to run on the right side of the vertebral column

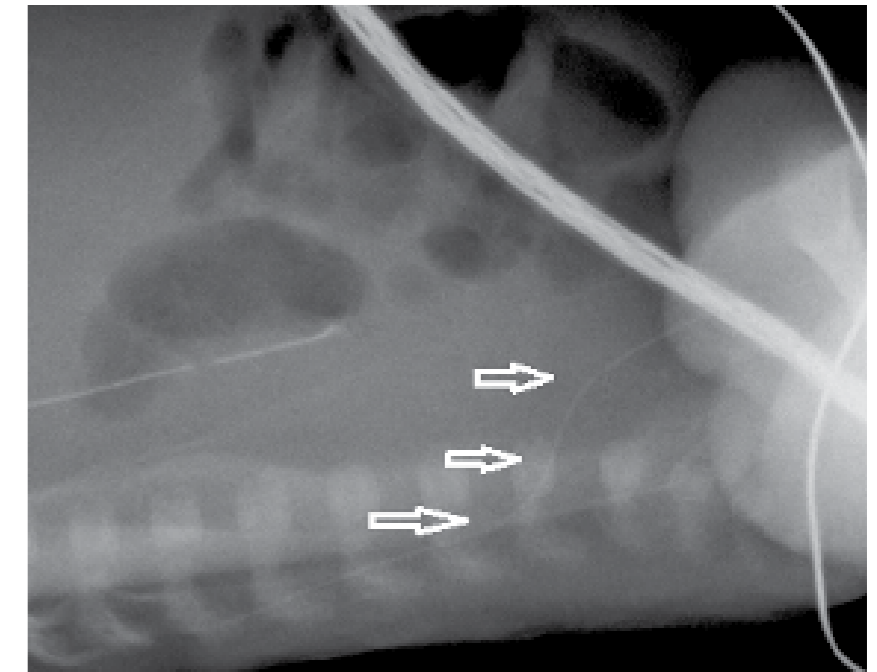


Image 4
A lateral x-ray demonstrating posterior deviation (arrows) of the PICC line towards the vertebral column

Lessons Learned

- The vast majority of cases of this complication have been reported in PICC lines placed in the left long saphenous vein. Where practical and possible consider insertion in other sites prior to using the left leg
- Extravasation of TPN / lipid into the CSF can cause varying neurological signs including irritability, abnormal movements, seizures and hypotonia
- The production of lipaemic fluid (either white "milky" coloured fluid or fluid with a high triglyceride content) from CSF is pathological and should alert clinicians to this rare complication
- Remove a PICC line promptly if this complication is suspected